

Drug treatment of macular degeneration

Robyn Guymer, Senior Lecturer, University of Melbourne, Head of Macular Research Unit, Centre for Eye Research Australia, and Medical Retinal Consultant, Royal Victorian Eye and Ear Hospital, Melbourne

SYNOPSIS

Many new therapies for age-related macular degeneration are under investigation as current treatment options are very limited. Photodynamic therapy is a new, effective and safe treatment for a select group of patients with choroidal neovascularisation associated with age-related macular degeneration. This treatment involves the selective accumulation of a photosensitive dye (verteporfin) within the abnormal vascular tissue rather than the surrounding normal tissue. When light of a specific wavelength is applied to the macula those areas containing greater amounts of dye undergo greater damage. This approach is superior to conventional argon laser photocoagulation where collateral thermal damage to vital structures limits its usefulness.

Index words: eye, photodynamic therapy, verteporfin.

(Aust Prescr 2002;25:116–9)

Introduction

Age-related macular degeneration (AMD) is a progressive, late-onset disease affecting central vision. It is currently the leading cause of irreversible blindness in Australia with 37% of registrable blindness (excluding refractive errors) being due to AMD compared to 21% due to glaucoma.¹ Early signs of the disease are present in 15% of the population aged 50 years and older, and by 90 years of age more than two-thirds of the population are affected. The prevalence of AMD is predicted to double in the next 30 years. The high prevalence, the anticipated increase in the ageing population and the very limited treatment options make AMD one of the greatest challenges in ophthalmology today.

Risk factors

The pathogenesis of AMD remains largely unknown. Environmental risk factors probably impact on the patient's genetic background.²

Twin and family studies as well as population-based genetic epidemiological studies have shown that genetic factors play an important role in the aetiology. However, the actual degree of heritability of AMD is still unknown.

The potential environmental risk factors are numerous, however smoking is currently the only factor consistently associated with AMD.³ Long-term smoking at least doubles the risk.

Other putative risk factors include hypertension, atherosclerosis, high serum cholesterol and dietary fat intake, light exposure, iris colour and a low intake of antioxidant vitamins. The Age Related Disease Study reported that high doses of multiple vitamins and zinc could marginally slow the progression of AMD in a sub-group of patients, although the high doses required (5–15 times recommended daily supplements) posed significant concerns about the adverse effects after long-term administration.⁴

Pathology

The early stages of macular degeneration can be recognised by the formation of drusen, yellow deposits, in the centre of the macula. They are very common and are not usually associated with visual symptoms. Significant visual loss occurs when a complication of the drusen develops, either a choroidal neovascular membrane, 'wet AMD' or atrophic 'dry AMD' (Fig. 1).

In neovascular AMD, abnormal blood vessels from the choroid grow up under the retina. This choroidal neovascular membrane causes acute loss of vision when transudate or haemorrhage accumulates beneath the retina, leading ultimately to a fibrous scar. This results in progressive and irreversible loss of central vision and often becomes bilateral over a period of years. The membranes are classified according to their appearance on a fluorescein angiogram (see box).

In atrophic AMD the retina slowly becomes atrophic over months to years and as such central vision is gradually lost. The majority of AMD is atrophic, however most of the patients with severe visual impairment have neovascular AMD.

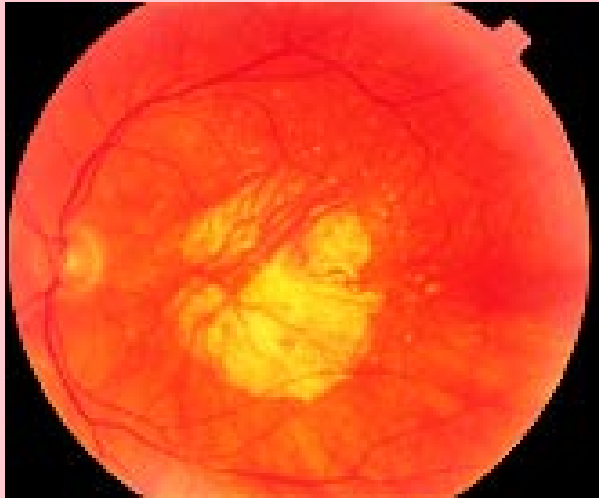Classification of choroidal neovascular membranes by fluorescein angiography

A classic lesion appears as a well demarcated area of uniform hyperfluorescence early in the angiogram with leakage of fluorescein later to obscure the boundaries of the lesion through the mid and late phases of the angiogram.

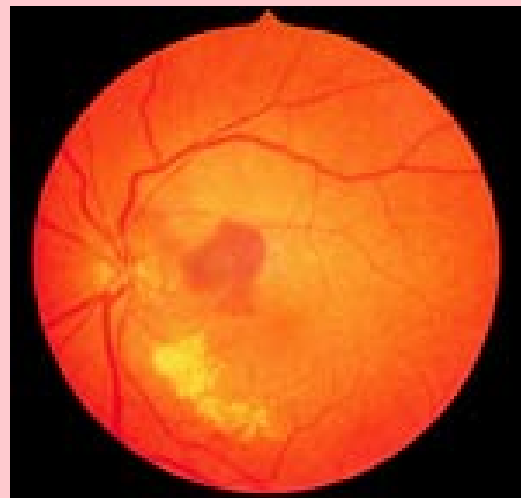
An occult (no classic component) lesion has poorly demarcated boundaries of fluorescein leakage from an undetermined source at the level of the retinal pigment epithelium in the late frames of the angiogram.

Fig. 1

a. A fundus photo depicting atrophic or 'dry' AMD



b. The central lesion in this fundus photo is depicting choroidal neovascularisation of the macula or 'wet' AMD



Treatment

The aim of treatment is to try and stop further loss of vision as once vision is lost it is usually not regained. We therefore need to screen people more effectively so that those at risk can be identified and educated about monitoring vision at home and the need for prompt referral. It is imperative to pick up symptoms of choroidal neovascularisation as soon as possible. Patients at high risk can be asked to observe an Amsler grid (square grid of lines) every few days to pick up changes as soon as they occur. Any sudden distortion of straight lines or missing parts of the chart should prompt swift action.⁵

Laser treatment

Large scale randomised clinical trials during the 1990s showed that argon laser photocoagulation was of benefit in neovascular AMD if the membranes were well defined on fluorescein angiography (classical membrane). The aim of photocoagulation is to limit the destructive effects of the choroidal neovascular membrane by using coagulative necrosis to destroy the entire neovascular complex. Heat conduction causes collateral damage to surrounding structures including the retina. Laser photocoagulation is therefore really only applicable if the abnormal blood vessels do not occupy the very centre of vision (subfoveal).

By the time patients with choroidal neovascularisation present to an ophthalmologist less than 20% will have a lesion that is suitable for conventional laser treatment. The vast majority of patients have subfoveal involvement at presentation. The use of laser photocoagulation for these subfoveal lesions is controversial. Despite immediate loss of acuity, long-term follow-up of more than two years shows treatment does have some benefit. Nevertheless the sudden iatrogenic acquisition of a dense central scotoma gives the patient no time to adapt to the loss of central vision. Whilst argon laser photocoagulation remains the treatment of choice for choroidal neovascular

membranes outside the fovea it has really failed to reduce the rates of blindness from AMD. This together with the fact that there is no proven treatment for atrophic AMD highlights the need for new treatments.

Photodynamic therapy

In photodynamic therapy a non-toxic light-sensitive compound called a photosensitiser is given intravenously and then subsequently activated by beaming light of an appropriate wavelength to the target area. There is a preferential concentration of the photosensitiser in the target tissue and light is directed towards this target area. Neither the light nor the drug is harmful to tissues when applied independently, but in combination they cause cellular destruction. The destructive mechanisms are complex and not well understood. They involve cellular, vascular and immunological actions, thereby differing substantially from the thermal damage caused by laser photocoagulation.

Although photodynamic therapy is a new technique, randomised clinical trials show it can reduce the risk of vision loss in cases of AMD with a choroidal neovascular membrane under the central fovea.^{6,7}

Photodynamic therapy is a two-step process that can be performed as an outpatient procedure. The first step involves a 10-minute intravenous infusion of the light-activated drug (verteporfin). Five minutes later the non-thermal laser (689 nm) is beamed for 83 seconds at 600 mW/cm to the lesion to achieve the desired light dose of 50 mJ/cm². The treatment size is the greatest linear dimensions of the lesion plus a 1 mm margin. Photoexcitation of the photosensitiser produces free radicals which cause structural and functional damage to cell membranes and other structures leading to cell death. The photodynamic damage to endothelial cells activates platelets leading to thrombus formation and vascular occlusion.⁸

Verteporfin

Verteporfin is a photosensitive drug derived from porphyrin. Its absorption maximum is in the ultraviolet A range (680–695 nm) so it can be activated by a non-thermal diode laser at wavelengths that can penetrate blood, melanin and fibrotic tissue. Once in the circulation verteporfin complexes with low density lipoproteins (LDL). As the number of endothelial LDL receptors is increased in neovascularisation, verteporfin preferentially accumulates in neovascular tissue. This increases the selectivity of photodynamic therapy for choroidal neovascular membranes and not other retinal vessels. The aim of verteporfin therapy is to occlude the abnormal vessels selectively while maintaining perfusion in deeper choroidal vessels and overlying retinal vessels. Unlike conventional laser treatment there is no immediate loss of vision at the site of verteporfin activation.

Early clinical trials showed that there was an immediate reduction in the fluorescent leak on angiography after treatment with verteporfin, however the effect was temporary. The leaks returned after 4–12 weeks. Re-treatment is therefore necessary for long-term benefits. Treatments are, on average, required every three months in the first 12 months and then twice in the second 12 months. One difficulty with this treatment is knowing when to stop. The present guidelines recommend that the treatment be continued, albeit at longer intervals, until there is no leak on the angiogram. At this stage it is not known if it is safe to stop before this occurs.

Clinical trials

Two phase III studies assessed the long-term safety and efficacy of verteporfin.^{6,7} The TAP study looks at photodynamic therapy for patients with classic choroidal neovascularisation while the VIP study looked at occult neovascularisation in AMD. So far, these studies show a modest benefit at two years in reducing the risk of moderate to severe visual loss.

The TAP study enrolled people with subfoveal choroidal neovascularisation that had a component that was defined as classic on the angiogram. For the purposes of the study, if at least 50% of the lesion had classical characteristics it was defined as predominately classic. Occult lesions were defined as no classic component and when less than 50% of the lesion had a classic appearance it was defined as minimally classic. In the study, the placebo group received a 30 mL solution of 5% dextrose in water over 10 minutes rather than the active photosensitiser, before the laser treatment was given.

The primary outcome was avoiding a loss of visual acuity of at least three lines on a modified ETDRS (early treatment diabetic retinopathy study) chart (approximately two lines lost on a standard Snellen chart). This outcome was achieved by 61% of the treated group and 46% of the placebo group over the first 12 months ($p < 0.001$). The patients with the best outcome, in a sub-group analysis, had a predominantly classical lesion on angiography; 67% of the treated group had a visual loss of less than three lines compared to 39% in the placebo group. Predominantly classical lesions constitute less than 25% of those with subfoveal choroidal neovascular membranes. There was no difference in minimally classical lesions and too few in the no classic component group to analyse meaningfully. In the VIP study the analysis of the 100% occult group, or no classic group, found a non-significant difference at 12 months of 49% of the treated group losing less than three lines of vision, compared to 46% of the placebo group.

After two years in the TAP study the predominantly classic group still showed a benefit of treatment with loss of less than three lines occurring in 59% of the treated compared to 31% of the placebo group. There was no significant difference in the minimally classic group (Table 1). In the VIP study, after two years 46% of patients with occult lesions treated with verteporfin had lost less than three lines of vision compared to 33% of the placebo group. These results provide the evidence to suggest that verteporfin treatment should be made available to people with predominantly classical membranes and, less convincingly, to those with no classic component in the membrane. There appears to be no benefit of this treatment for lesions with a minimally classical component.

Verteporfin appears to be reasonably safe. There are reports of infusion-related back pain and photosensitivity reactions in 2–3% of patients. All patients must avoid sunlight for 48 hours after the treatment as they can suffer severe sunburn if they are exposed to the sun before the photosensitive dye is eliminated. The pharmacokinetic profile is slightly altered in patients with mild hepatic impairment as biliary clearance is the main route of elimination. However, there was not an associated increase in skin photosensitivity in these patients. There is no experience of verteporfin in people with moderate to severe liver impairment, therefore caution should be taken and measures to prevent photosensitivity reactions should be adhered to longer. It is possible that the concomitant use of other photosensitive drugs (such as tetracyclines, sulfonamides, thiazide diuretics) may increase the potential for photosensitive reactions.

Table 1

Efficacy of verteporfin in photodynamic therapy

Primary visual outcome results at two years by sub-group analysis (less than three lines of vision lost)⁶

<i>Type of neovascularisation</i>	<i>Verteporfin treated group</i>	<i>Placebo</i>	
Predominantly classic	59% (94)	31% (26)	$p < 0.001$
No classic	46% (104)	33% (38)	$p < 0.23$
Minimally classic	47.5% (96)	44.2% (46)	$p < 0.58$

(Number of eyes = number of patients)

In Australia verteporfin dye costs \$2000 per vial. Since June 2002 the Commonwealth Government has decided to subsidise verteporfin for patients with predominantly classic neovascularisation. Ophthalmologists will have to send in their angiograms for assessment by a panel to gain this subsidy for the patient. At present there is no subsidy for purely occult, or no classic neovascularisation.

There are reports of a 5% risk of sudden severe visual loss after treatment in the group with no classic component. This is important considering the smaller benefit likely from treating this sub-group.

Experimental medical treatments

With the number of people in the at risk age group set to double in the next 25 years we need to look for more effective ways to manage AMD. New photosensitisers such as SnET2 (tin ethyl etiopurpurin) and lutetium texaphyrin are currently being investigated. Angiogenesis inhibitors are being studied in the hope that they can stop choroidal neovascularisation. Vascular endothelial growth factor (VEGF) plays an important role in the retinal and iris neovascularisation caused by retinal ischaemia as in diabetic retinopathy. Evidence is accumulating to implicate VEGF as a principal angiogenic growth factor contributing to the pathology of AMD. A large multicentred randomised controlled trial of intravitreal injections of an anti-VEGF is underway.

Conclusion

Clinical trials have shown that verteporfin therapy reduces the risk of at least moderate visual loss compared to placebo for at least two years in patients with predominantly classic choroidal neovascular membranes who present with subfoveal lesions. Verteporfin does not repair already damaged tissues, but might prevent further growth of the membranes. Photodynamic therapy adds a technique to the ophthalmologists' armamentarium for some lesions in AMD for which there is virtually no other proven treatment. Conventional laser photocoagulation treatment still remains the best choice for nonfoveal, classic choroidal neovascularisation. As phototherapy reduces the risk of vision loss rather than restoring vision, it is essential to identify the development of choroidal neovascular membranes as quickly as possible so the patient can be treated while their visual acuity is still good. Verteporfin is not a 'miracle cure', but it is at least a step in the right direction. Patient education is crucial to try and avoid unrealistic expectations from the treatment. There are still unsolved issues with photodynamic therapy such as the optimal treatment regimen and the effect on the patient's quality of life.

REFERENCES

1. Weih LM, VanNewkirk MR, McCarty CA, Taylor HR. Age-specific causes of bilateral visual impairment. *Arch Ophthalmol* 2000;118:264-9.
2. Evans JR. Risk factors for age-related macular degeneration [review]. *Prog Retin Eye Res* 2001;20:227-53.
3. Smith W, Mitchell P, Leeder SR. Smoking and age-related maculopathy. The Blue Mountains Eye Study. *Arch Ophthalmol* 1996;114:1518-23.
4. Age-Related Eye Disease Study Research Group. AREDS Report No. 8. A randomized, placebo-controlled, clinical trial of high-dose supplementation with vitamins C and E, beta carotene, and zinc for age-related macular degeneration and vision loss. *Arch Ophthalmol* 2001;119:1417-36.
5. Soubrane G, Bressler NM. Treatment of subfoveal choroidal neovascularisation in age related macular degeneration: focus on clinical application of verteporfin photodynamic therapy [review]. *Br J Ophthalmol* 2001;85:483-95.
6. Treatment of age-related macular degeneration with photodynamic therapy (TAP) study group. Photodynamic therapy of subfoveal choroidal neovascularization in age-related macular degeneration with verteporfin. Two-year results of 2 randomized clinical trials – TAP report 2. *Arch Ophthalmol* 2001;119:198-207. (randomised trial)
7. Verteporfin in photodynamic therapy study group. Verteporfin therapy of subfoveal choroidal neovascularization in age-related macular degeneration: two-year results of a randomized clinical trial including lesions with occult with no classic choroidal neovascularization – verteporfin in photodynamic therapy report 2. *Am J Ophthalmol* 2001;131:541-60. (randomised trial)
8. Schmidt-Erfurth U, Hasan T. Mechanisms of action of photodynamic therapy with verteporfin for the treatment of age-related macular degeneration. *Surv Ophthalmol* 2000;45:195-214.

Dr Guymer is a research fellow supported by the Royal Victorian Institute for the Blind.

Self-test questions

The following statements are either true or false (answers on page 123)

5. Most cases of age-related macular degeneration are caused by abnormal blood vessels growing from the choroid.
6. Patients should avoid sunlight for 48 hours after treatment with verteporfin.

Message to all 2002 graduates in medicine, pharmacy and dentistry

If you are graduating in Australia this year and you wish to continue receiving *Australian Prescriber* to assist with your postgraduate training, please complete and send the distribution form on the inside back cover of this issue, or register on-line at www.australianprescriber.com at Contact Us.

Australian Prescriber storage boxes

Many readers of *Australian Prescriber* keep their copies for reference. To help readers keep their back issues in good condition, a limited number of vinyl covered storage boxes are now available for Australian readers only. The boxes will hold all the issues published over the last 5 years. To order a box, send your name and address to the Editorial office (see page 123). A limit of one box per Australian reader will apply.